

Shaping and Restoring Ovoid Canal Systems

David J. Clark, DDS*

Traditional endodontics has been based on feel, not sight. Tactile proprioception was the clinician's only guide as burs and files were blindly inserted into pulp chambers and root canal systems (Figures 1 and 2). Together with radiographs and electronic apex locators this blind approach has produced surprising success. There is, however, a significant failure rate, especially long-term failure that is driving mainstream dentistry to aggressively extract natural teeth in favor of implants. The sting of clinical failure is a powerful motivator for change.

A VISUAL APPROACH

Today, a small but growing number of clinicians are providing endodontic and endo-restorative treatments based on direct microscopic visualization of the pulp chamber and coronal portions of canal systems. This huge shift in clinical accuracy is bringing a revolution to the field of endodontics which will soon be followed by endo-restorative upheaval and evolution.

RIBBONS, SHEETS, AND BANNERS

One of the most distressing “hangovers” of the era of blind endodontics and endo-restorative treatments is the belief that canal systems are straight, exit at the radiographic apex, and are

round in cross section. In reality, most canal systems curve and exit short of the radiographic terminus. A very large number (at least 50%) are ovoid or super-ovoid in cross section. Of the three roots and canal systems shown, only one is round (Figure 3). As these canal systems mature, they narrow into a variety of unpredictable ovoid shapes—often with smaller anastomosing canal systems.

OVOID CANAL SYSTEMS AND ROOTS ARE NON-ROUND FOR A REASON

Rotary instruments and obturating points of gutta-percha are round because of the limitations of their mechanical nature. They create anatomically appropriate shapes in round roots, but can fail in ovoid roots. Over the ages, the dynamics of occlusion and arch form have guided the development of human tooth roots such that at least half have ovoid roots (Figure 4).

OVOID SHAPING: WHY

Biomimetics is a treatment approach that has, as its ultimate goal, to retain as much of the natural tissue as practical and to also mimic the physics and structures of the human body.

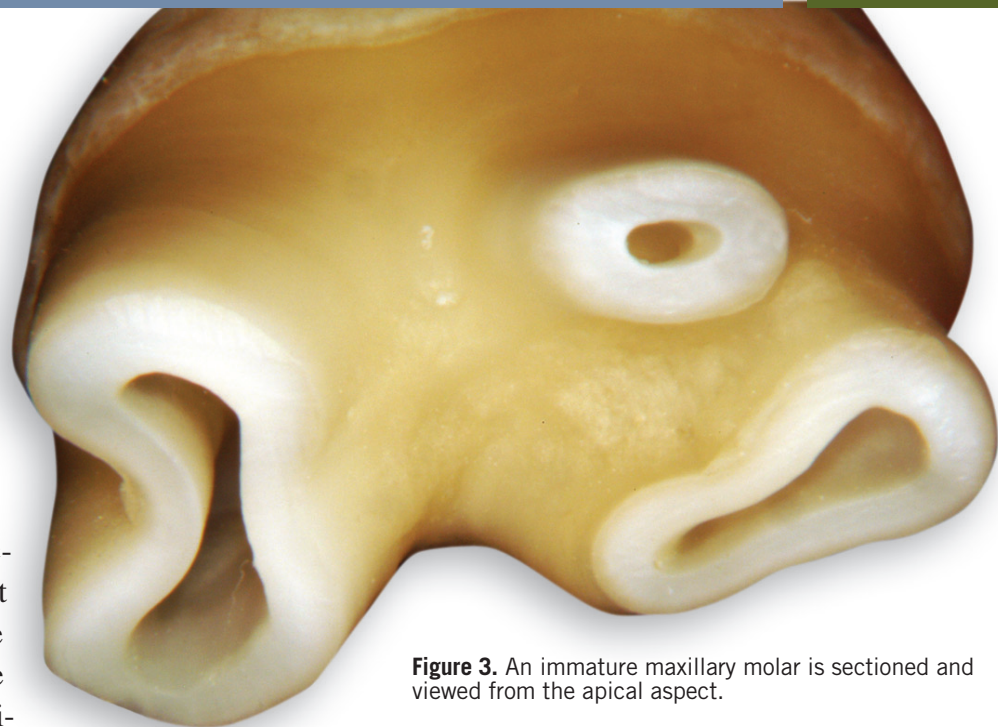


Figure 3. An immature maxillary molar is sectioned and viewed from the apical aspect.

There is nothing biomimetic about a stiff, round rod (ie, prefabricated post) running through the center of an ovoid root. The natural ovoid root is essentially a stiff pipe deriving its strength from without, not within. The endodontic and endo-restorative goal should be to mimic the pulp space that was present when the tooth was young. From that point, it can be argued that any secondary dentin that is deposited adds little additional strength because of the amorphous and irregular deposition pattern. This point is supported by the robust strength of young teeth with large pulp chambers and large radicular pulp spaces.

If a small round access that does not disturb primary dentin can allow instruments to engage potentially significant complex anatomy (eg, a second or third major system and corresponding portals of exit), then the round access is acceptable. The reality of ovoid roots, however, would seem to disagree with this approach. Creating a large round access that results in the removal of the primary dentin of the delicate, narrow portion of the root is a common approach today. While this can allow access to complex branching of systems that occurs further apically, it does not satisfy the more appropriate goals of anatomic, biomimetic dentistry. Additionally, the large, round endodontic shaping pattern often encroaches upon a fluting in the center of the root.

VISUALLY SHAPING OVOID SYSTEMS

The three components of ovoid shaping are: 1) the operating microscope with powerful coaxial shadowless lighting, 2) ultrasonic instruments, and 3) an understanding of the anatomy of ovoid roots. Anatomic, biomimetic shaping cannot occur safely “by feel”. While

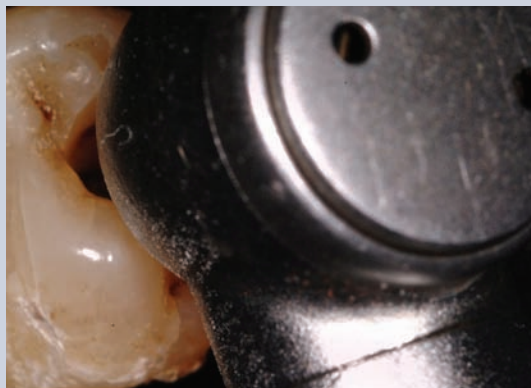

Figure 1. A traditional handpiece with typical visual obstruction of the internal of the tooth.

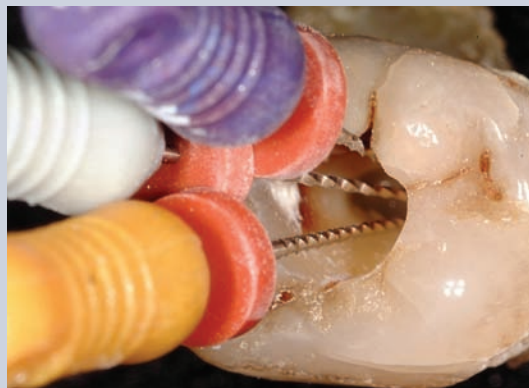

Figure 2. The inserted files block proper visualization of canal systems.

attempts are possible with lesser technologies such as oculars (loupes), headlights, and rotary instruments, the era of microscope-enhanced dentistry ushers in new possibilities. It is time to embrace these previously unthinkable potentials in clinical accuracy.

The canal system is ovoid in the coronal half then bifurcates into two distinct canal systems in mid-root (Figures 5 through 9). The unmodified, shrouded orifice and alignment of the buccal system will direct instruments into only that system. Traditional *round* access of this tooth will normally result in little to no cleaning, shaping, or obturation of the lingual canal system. All ovoid systems should be suspect for this type of anatomy, and at a minimum may have multiple portals of exit that may not be well addressed with a single round canal preparation (Tables 1 and 2).

“ Today, a small but growing number of clinicians are providing endodontic and endo-restorative treatments based on direct microscopic visualization of the pulp chamber and coronal portions of canal systems.”

The lack of coaxial shadowless lighting, magnification at less than 10 \times , the visual impairment of the bulky head of the traditional handpiece, and the limitations of the flimsy shank of Gates Glidden burs, the gouging effect of round burs, all together create the barbaric shapes of the past.

SMASHED CONES AND TRUMPETS

The modern endodontic shape is often either a tapering cone or a trumpet. This is appropriate in group one (round) canal system shapes. For the group two (ovoid and super ovoid), the goal is to create a *smashed* trumpet or a *smashed* cone (Figure 10).

THE IDEAL POST AND OTHER MYTHS

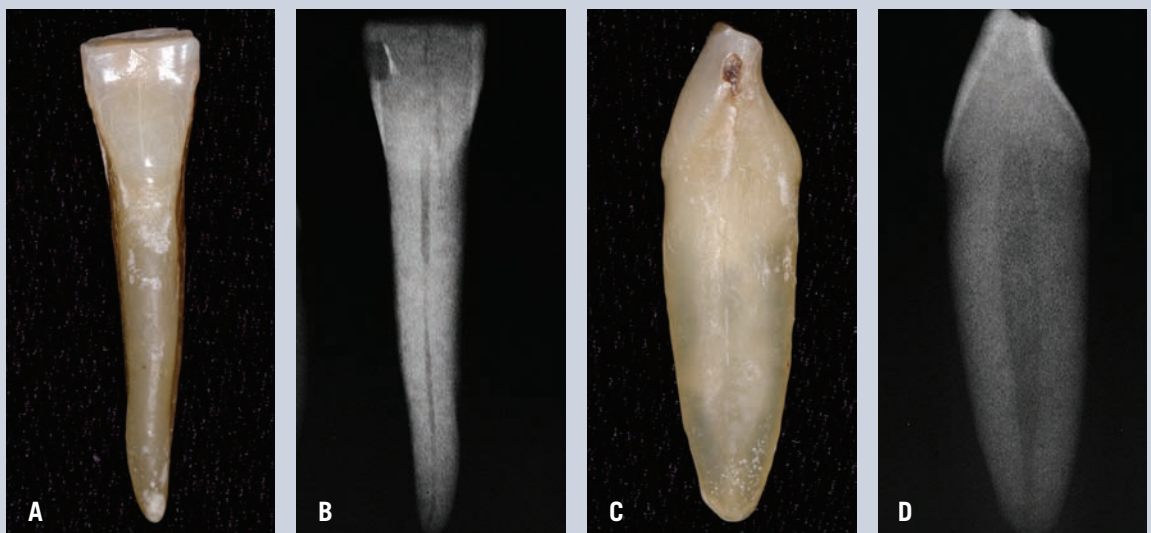
The ideal post is no post. Posts will remain a viable restorative modality but unfortunately have been used to compensate for

Table 1. New Microscope Enhanced Protocol.

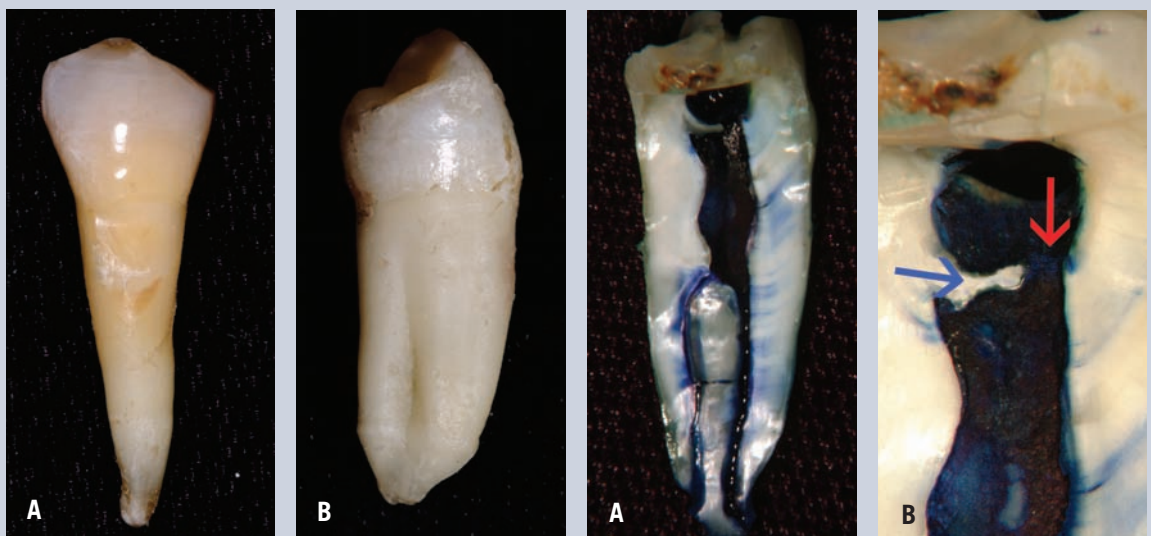
1. Access with round-ended carbide or diamond burs;
2. Gross deroofing with larger surgical length round burs;
3. Fine deroofing with Obtura Spartan CPR-2D;
4. De-mouseholing with CPR-2D;
5. De-Shroud with CPR-2D; and
6. Provide straight line access sweeping away from high risk anatomy with the CPR-2D.

FOR OVOID SYSTEMS

7. Sweep the coronal 1/4 of the ovoid system with the CPR-2;
8. Sweep the next 1/4 or 1/2 with the CPR-4D or 5D;
9. Irrigate, dry with the Stropko syringe, and then evaluate at 16 \times to 24 \times for multiple systems that branch in the apical half;
10. Insert appropriate, curved files while carefully maintaining patency;
11. Take radiographs from three angles;
12. Second opinion with apex locator; and
13. Begin filing.



Figures 4A-4D. This mandibular incisor that appears so frail with a lingual view or facially taken radiograph appears husky with a mesial view. It is at least twice as broad buccolingually.



Figures 5A and 5B. Buccal and mesial views of a fairly typical lower bicuspid.

Figures 6A and 6B. A sectioned root and dyed pulp which demonstrate an ovoid system that separates into two distinct canal systems in mid root. The red arrow highlights the pathway when a round access is made while the blue arrow highlights the shrouded lingual half of the orifice that will direct all instruments toward the buccal in the traditional tactilely driven, round preparation.

Table 2. Advantages to the New Microscope—Enhanced Protocol.

- Most files drop easily to the root terminus because the coronal restriction is actually the most common cause of a canal that feels “calcified”;
- File breakage is extremely rare;
- Tactile sense of the apical constriction is more accurate;
- The canal system is shaped anatomically instead of simply creating a blind funnel;
- A second set of radiographs is not needed. The “shortening” of the length of a curved canal system has already occurred before files are inserted and measured;
- Instead of making a round coronal shape, the anatomically correct ovoid shape allows hand files and rotary files to be tipped buccally and lingually (or mesially and distally in some palatal roots) to predictably find, shape, and obturate the major canal systems; and
- Ovoid shaping allows significant file curvature to be maintained as files are inserted to negotiate potential “dog-leg” portals of exit (Figure 11).

ULTRASONIC ADVANTAGES

- The unique nature of the long diamond coated shape allows de-roofing, de-mouseholing and de-shrouding without gouging; and
- The bulky head of the handpiece is no longer a limiting visual impediment.

the unnecessary weakening that traditional endodontic access and shaping has inflicted on radicular and periradicular dentin. Too much attention is being paid to posts as the solution to endo-restorative treatment. Biomimetics is moving *away* from posts altogether. Two important myths that need to be addressed are:

1. The dentin in nonvital teeth becomes brittle. Untrue. Dentin in nonvital teeth performs the same as in vital teeth. When endodontics and restoratives can be performed delicately, the tooth should have a similar life expectancy to a vital tooth.¹⁻³

2. A post strengthens the root. Also untrue. The purpose of a post is to retain the core in case of lack of ferrule. With delicate endodontic shapes and delicate axial crown preparations, research has shown that *no post* is as strong as *with post*, as long as adequate ferrule is present (Table 3).⁴

POSTS IN MOLARS

Molars generally possess adequate internal retention to retain the core. Prefabricated post use is therefore usually not necessary and should be avoided. The best post is no post if

the core can be adequately retained by the stump and adequate ferrule is created to retain the crown or onlay.

POSTS, POST SPACE, AND OVOID CANAL SYSTEMS

Currently, there are six options for restoring ovoid systems:

1. **Paste composite, amalgam, or similar direct filling materials**—Provides an unacceptable compromise unless there is generous ferrule present. Direct filling materials can only provide a restorative seal; none of the products currently on the market possess sufficient fracture toughness to act as a “post”;
2. **Use of a small prefabricated post that lacks adequate resistance form⁵**—Provides an unacceptable compromise unless there is generous ferrule present. Research has shown that resistance form is far more important for successful posts than is retention form;
3. **Modifying (enlarging) the canal system to fit a prefabricated post**—Reaming an ovoid canal shape simply because posts are round is no longer acceptable. Current opinion leaders are rapidly moving toward the principle of little to no removal of dentin for creation of post space;
4. **Modification of the post to fit the canal shape**—Grinding a large round metallic post into an ovoid shape is a bit time consuming, requires pressure-indicating products, and requires high level magnification and patience. This approach is not recommended for the new fiber posts. This is because all of the real strength of these posts is derived from uninterrupted fibers. “Carving” these posts will result in a severe compromise in flexural strength;

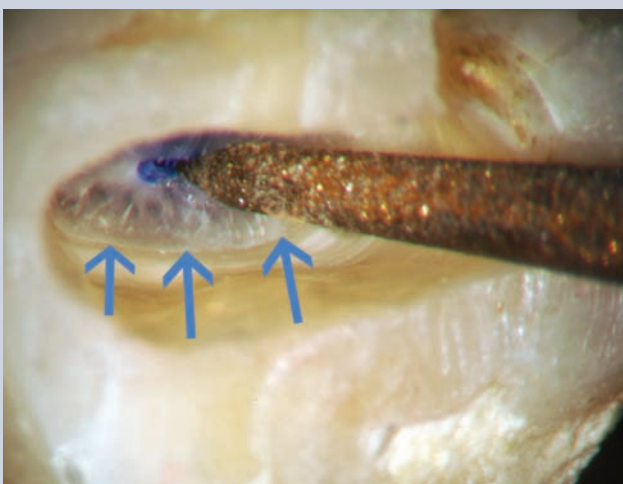


Figure 7. Contralateral bicuspid is shaped to follow the pattern of secondary dentin as resembling “glacial ice” in appearance under the microscope. CPR—2D ultrasonic tip is pictured at 16×.

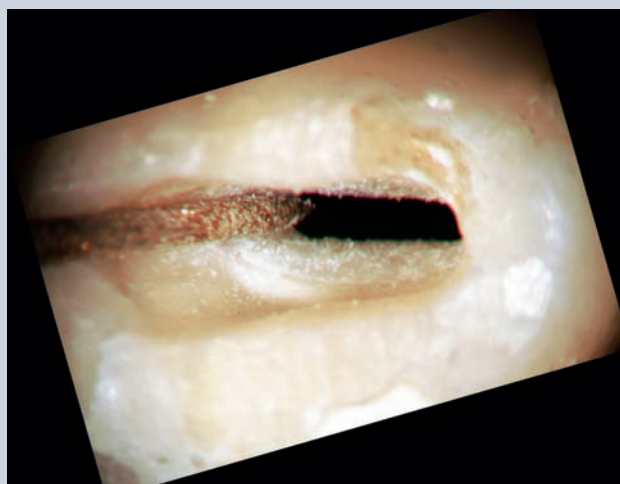


Figure 8. Depicts the finer CPR—5D as the ovoid system is explored further apically with constant microscopic visualization.

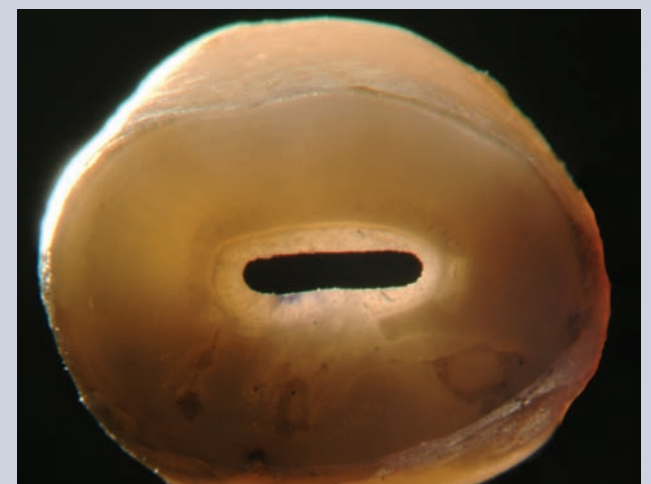


Figure 9. Apical view at 16× after sectioning the root in the coronal third. Ovoid shaping has retained a thin border of secondary dentin.

Table 3. Endodontic Shapes and Posts

<p>Round, mildly tapered roots or canal systems: Acceptable candidates for round shaping and prefabricated posts:</p> <ul style="list-style-type: none"> • Maxillary central incisors • Maxillary canines • Maxillary lateral incisors • Maxillary first bicuspid with two canal systems • Maxillary molars: Palatal canal systems 	<p>Ovoid and/or highly tapered roots that can be marginal candidates for round shaping and prefabricated posts</p> <ul style="list-style-type: none"> • Mandibular molars: Distal canal systems • Mandibular incisors • Mandibular canines 	<p>Exclusively ovoid and/or highly tapered roots that are usually poor candidates for round shaping and prefabricated posts</p> <ul style="list-style-type: none"> • “Young” mandibular incisors and mandibular canines with super-ovoid canal systems • Mandibular bicuspid • Maxillary second bicuspid 	<p>Highly curved and/or delicate roots that are poor candidates for prefabricated posts:</p> <ul style="list-style-type: none"> • Mandibular molar: Mesial canal systems • Maxillary molar: mesio-buccal, mesio-palatal (MB2) and distal canal systems
---	---	---	--

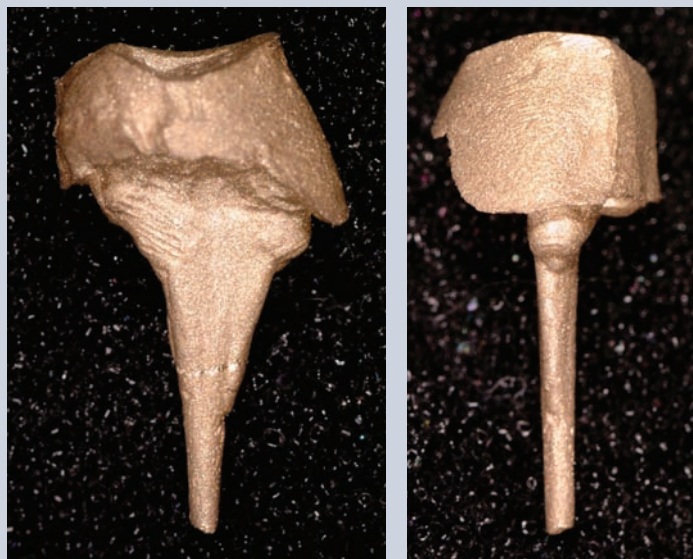


Figure 10. An endo-restorative casting with a *smashed trumpet* shape from a lower bicuspid is demonstrated in facial and oblique views.

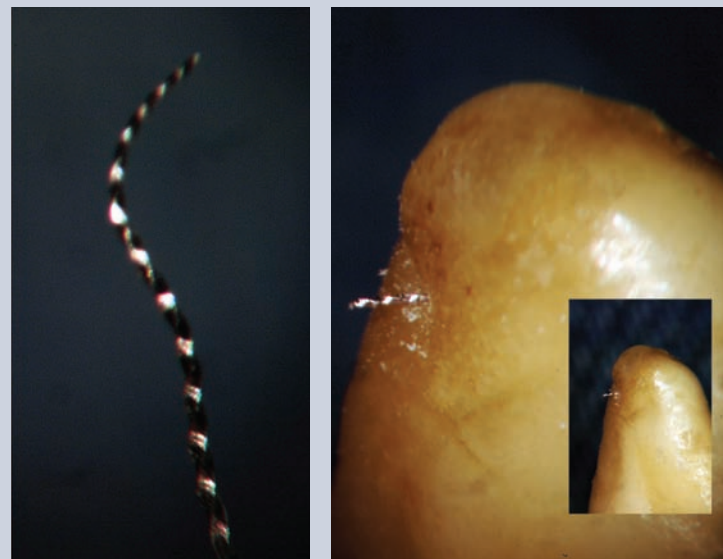


Figure 11. Exotic file curvature is maintained because of ovoid shaping before file is inserted.

5. Use of multiple small round posts— This approach remains reasonable. It can, however, be cumbersome and very challenging. The final result can often yield resistance form that is somewhat compromised; and

6. The endo-restorative casting—A new technique that is founded on microscopic visualization. These beautiful and often bizarre shapes follow the forms that nature originally created. The design gives ideal, varying moduli of elasticity from apical to occlusal that flexes in the apical portion but provides unparalleled stiffness in the build-up portion.

SUMMARY

Although no two roots are the same, general anatomic patterns allow the microscope-equipped clinician to search for major pulpal regions that will yield a high probability

of cleaning and shaping the clinically available pulpal zones. There are complex, anatomically improbable, and clinically impossible areas of pulp that are beyond the reach of even the most gifted hands and microscope eyes. The good news is that nature is often very forgiving. Regardless, the clinician has the responsibility to begin each procedure seeking perfection and joyfully finishing with excellence. The shapes that were introduced during the Schilder era have served as a transitional technique to allow the first real three dimensional compaction of gutta-percha. Endodontics is, in reality, a *restorative* driven procedure and, in the end, the Schilder shape creates beautiful endodontics but dramatically compromises the long-term restorative potential. The shaping philosophy advanced in this treatise allows perfectly adequate shapes to achieve the

hydraulics needed for modern obturation. It will require different skills and materials to shape, pack, and restore these non-round systems. ■

REFERENCES

1. Sathom S, Palamara JE, Messer HH. A comparison of the effects of two canal preparations on root fracture susceptibility and fracture pattern. *J Endod* 2005;31(4): 283-287.
2. Sedgley CM, Messer HH. Are endodontically treated teeth more brittle? *J Endod* 1992;18(7):332-335.
3. Huang TJ, Schilder H, Nathanson D. Effects of moisture content and endodontic treatment on some mechanical properties of human dentin. *J Endod* 1992;18(5): 209-215.
4. Heydecke G, Butz F, Strub JR. Fracture strength and survival rate of endodontically treated maxillary incisors with approximal cavities after restoration with different post and core systems: an in-vitro study. *J Dent* 2001;29(6):427-433.
5. Lambjerg-Hansen H, Asmussen E. Mechanical properties of endodontic posts. *J Oral Rehabil* 1997;24(12): 882-887.